

*УДК 616-01:618:615.9:616-06:616.4*

**Dr. Abdelrahman M. Radaideh**, MD, JBIM, JBED Arrayn Hospital, Endocrine Division, Medical Department, Arrayan Hospital, Sulaiman Habib Medical Group, Riyadh, Saudi Arabia Khurais Road P.O.Box 10026, Riyadh 11635 Saudi Arabiaemail: radaideha@gmail.com. Tel: +966568104210.

ORCID: <https://orcid.org/0000-0001-8068-5449>

**Dr. Mohamad Nusier**, Professor, MD., PhD. Department of Biochemistry Jordan University of Science and Technology, School of Medicine P.O.Box 3030, Irbid 22110, Jordan email: mick@just.edu.jo Cell: +962 797136666 . \*Corresponding author. Disclosures: Authors have no conflict of interest.

ORCID: <https://orcid.org/0000-0002-2140-0236>

**POSTPARTUM HYPOPITUITARISM AND EMPTY SELLA IN TYPE 1  
DIABETIC PATIENT, AUTOIMMUNE HYPOPHYSITISOR  
ANTEPARTUM PITUITARY NECROSIS? A CASEREPORT**

**Short running title: POSTPARTUM HYPOPITUITARISM, EMPTY SELLA  
IN TYPE 1 DIABETIC PATIENT**

**Annotation**

**Dr. Abdelrahman M. Radaideh**, MD, JBIM, JBED Arrayn Hospital, Endocrine Division, Medical Department, Arrayan Hospital, Sulaiman Habib Medical Group, Riyadh, Saudi Arabia. **Dr. Mohamad Nusier**, Professor, MD., PhD. Department of Biochemistry Jordan University of Science and Technology, School of Medicine, Jordan. **Postpartum Hypopituitarism, Empty Sella in Type 1 Diabetic Patient.**

**Key words:** hypopituitarism, type 1 diabetes mellitus, pituitary necrosis, hypophysitis, empty Sella, central hypothyroidism, amenorrhea.

**Formulation of the problem.** Panhypopituitarism is a rare endocrine disease with variable clinical presentations, ranging from asymptomatic to life threatening condition. Postpartum Panhypopituitarism (Sheehan's syndrome) is a well-known clinical condition that has been attributed to massive ante or postpartum hemorrhage.

Postpartum hypopituitarism on the other hand, which develops after normal delivery, is a rare condition. It is mostly attributed to lymphocytic hypophysitis. In Type 1 DM patients that has been attributed to antepartum pituitary necrosis, which is a very rare condition.

**Analysis of recent research and publications.** Lymphocytic hypophysitis or autoimmune hypophysitis is a disease characterized by lymphocytic infiltration of the pituitary gland, which eventually leads to destruction of pituitary tissue accompanied by various clinical presentations of pituitary dysfunction.

**Formulating the purpose of the article.** The purpose is to present a case of hypopituitarism and empty Sella in a Type1 diabetic patient, diagnosed postpartum after long-suffering, who has achieved full term pregnancy and normal delivery is reported. Diagnosis of lymphocytic hypophysitis or antepartum pituitary necrosis was raised as the cause of the hypopituitarism.

**Presenting main material.** Here we describe a case of Type 1 diabetic patient with postpartum panhypopituitarism and empty Sella. The condition may be related to either autoimmune hypophysitis or anterior pituitary necrosis during pregnancy.

**Discussion:** Is this a case of Lymphocytic Hypophysitis during pregnancy? - because she was on her second trimester of pregnancy! She developed severe headache, nausea, vomiting, general weakness with hypoglycemic attacks, and sensitive hyperglycemia (where only small doses of insulin are needed to control that) with symmetrical pituitary enlargement which was seen in Brain MRI even contrast was not given. The patient's condition was explained as non-specific aseptic meningitis. The endocrine deficiency in our patient was due to anterior pituitary hypopituitarism, initially manifested by amenorrhea, failure of lactation

and later diagnosed as ACTH and TSH deficiency. Growth hormone and IGF1 were not evaluated at that time. This case is a diagnostic feature of autoimmune hypophysitis panhypopituitarism.

**Conclusions and perspectives of further research.** We conclude that any headache of sudden onset associated with nausea and vomiting during pregnancy and a suggested picture of pituitary insufficiency should be considered an alert of pituitary disorder that cannot be explained as pregnancy related symptoms, or non-specified meningitis. Furthermore, to be careful in interpreting images not specific to pituitary gland. This conclusion was established based on the early steroids treatment that could prevent the progression of the pituitary destruction and/or early identification of the condition with early replacement therapy. This should prevent long-suffering of such patients.

#### **Анотація**

**Доктор Абдельрахман М. Радайдех**, доктор медичних наук, JBIM, JBED Arrayn Hospital, ендокринний відділ, медичний відділ, лікарня Arrayn, медична група Sulaiman Habib, Ер-Ріяд, Саудівська Аравія. **Доктор Мохамед Нусейр**, професор, доктор медичних наук. Кафедра біохімії, Університет науки і техніки Йорданії, Медичний факультет, Йорданія. **Післяпологовий гіпопітуїтаризм у пацієнок із цукровим діабетом 1 типу.**

**Ключові слова:** гіпопітуїтаризм, цукровий діабет 1 типу, некроз гіпофіза, гіпофізит, порожня селла, центральний гіпотиреоз, аменорея.

**Постановка проблеми.** Пангіпопітуїтаризм є рідкісним ендокринним захворюванням з різними клінічними уявленнями, від безсимптомного до загрозливого до життя стану. Післяпологовий пангіпопітуїтаризм (синдром Шихана) - добре відомий клінічний стан, який пояснюється масовим до- або післяпологовим крововиливом. Післяпологовий гіпопітуїтаризм, з іншого боку, який розвивається після нормальних пологів, є рідкісним станом. В основному це пояснюється лімфоцитарним гіпофізитом. У хворих з

цукровим діабетом 1-го типу було описано некроз гіпофіза, який є дуже рідкісним.

**Аналіз останніх досліджень і публікацій.** Лімфоцитарний гіпофізит, або аутоімунний гіпофізит - це захворювання, що характеризується лімфоцитарною інфільтрацією гіпофіза, яка в кінцевому підсумку призводить до руйнування гіпофізарної тканини, що супроводжується різними клінічними проявами гіпофізарної дисфункції.

**Формулювання мети статті.** Мета полягає в тому, щоб представити випадок гіпопітуїтаризму в пацієнки з діабетом типу 1 в післяпологовому періоді, після нормальних пологів, причиною якого було визнано лімфоцитарний гіпофізит або некроз гіпофіза *ante partum*.

**Викладення основного матеріалу.** Тут ми описуємо випадок хворої на цукровий діабет 1-го типу з післяпологовим пангіпопітуїтаризмом. Стан може бути пов'язаний або з аутоімунним гіпофізитом, або з некрозом передньої долі гіпофіза під час вагітності.

**Обговорення:** Важкий стан пацієнтки пояснювався неспецифічним асептичним менінгітом. Ендокринний дефіцит був обумовлений гіпопітуїтаризмом передньої долі гіпофіза, що спочатку проявлялося аменореєю, невдачею лактації і пізніше було діагностоване як дефіцит АКТГ і ТТГ. Цей випадок є діагностичною ознакою пангіпопітуїтаризму, аутоімунного гіпофізиту.

**Висновки та перспективи подальших досліджень.** Ми робимо висновок, що будь-який головний біль від раптового початку, пов'язаного з нудотою і блювотою під час вагітності, слід вважати попередженням гіпофізарного розладу, який не можна пояснити симптомами, пов'язаними з вагітністю, або менінгітом. Раннє лікування стероїдами може запобігти прогресуванню гіпофізарного руйнування та багаторічним стражданням таких хворих.

## **Аннотация**

**Доктор Абдельрахман М. Радайех**, доктор медицинских наук, JBIM, JBED Arrayn Hospital, эндокринный отдел, медицинский отдел, больница Arrayan, медицинская группа Sulaiman Habib, Эр-Рияд, Саудовская Аравия. **Доктор Мохамед Нусейр**, профессор, доктор медицинских наук. Кафедра биохимии, Университет науки и техники Иордании Медицинский факультет, Иордания.

**Послеродовой гипопитуитаризм у пациенток с сахарным диабетом 1 типа.**

**Ключевые слова:** гипопитуитаризм, сахарный диабет 1 типа, некроз гипофиза, гипофизит, центральный гипотиреоз, аменорея.

**Постановка проблемы.** Пангипопитуитаризм является редким эндокринным заболеванием с различными клиническими проявлениями, от бессимптомного до угрожающего жизни состояния. Послеродовой пангипопитуитаризм (синдром Шихана) - хорошо известное клиническое состояние, которое объясняется массовым до- или послеродовым кровоизлиянием. Послеродовой гипопитуитаризм, с другой стороны, который развивается после нормальных родов, является редким состоянием. В основном это объясняется лимфоцитарным гипофизитом. У больных с сахарным диабетом 1-го типа был описан некроз гипофиза, который встречается крайне редко.

**Анализ последних исследований и публикаций.** Лимфоцитарный гипофизит, или аутоиммунный гипофизит - это заболевание, характеризующееся лимфоцитарной инфильтрацией гипофиза, которая в конечном итоге приводит к разрушению гипофизарной ткани, сопровождающееся различными клиническими проявлениями гипофизарной дисфункции.

**Формулировка цели статьи.** Цель состоит в том, чтобы представить случай гипопитуитаризма у пациентки с диабетом типа 1 в послеродовом периоде, после нормальных родов, причиной которого был признан лимфоцитарный гипофизит или некроз гипофиза antepartum.

**Представление основного материала.** Здесь мы описываем случай больной сахарным диабетом 1-го типа с послеродовым пангипопитуитаризмом. Состояние может быть связано или с аутоиммунным гипофизитом, или с некрозом передней доли гипофиза во время беременности.

**Обсуждение:** Тяжелое состояние пациентки объяснялось неспецифическим асептическим менингитом. Эндокринный дефицит был обусловлен пангипопитуитаризмом передней доли гипофиза, что вначале проявлялось аменореей, неудачей лактации, а позже было диагностировано как дефицит АКТГ и ТТГ. Этот случай является диагностическим признаком пангипопитуитаризма, аутоиммунного гипофизита.

**Выводы и перспективы дальнейших исследований.** Мы делаем вывод, что любую головная боль с внезапным началом, связанную с тошнотой и рвотой во время беременности, следует считать предупреждением гипофизарного расстройства, что нельзя объяснить симптомами, связанными с беременностью, или менингитом. Раннее лечение стероидами может предотвратить прогрессирование гипофизарного разрушения и многолетние страдания таких больных.

**Key words:** hypopituitarism, type 1 diabetes mellitus, pituitary necrosis, hypophysitis, empty Sella, central hypothyroidism, amenorrhea.

**Formulation of the problem.** Postpartum pituitary necrosis or Sheehan's syndrome is a familiar condition that has been attributed to massive bleeding during or after the delivery [1]. The specific mechanism of pituitary necrosis is unclear and generally accepted, that hypotension increases pituitary ischemia leading to necrosis, which may cause hypopituitarism immediately or years later, depending on the degree of tissue damage [2]. Antepartum pituitary necrosis, which is unrelated to massive intra or postpartum hemorrhage, is a very rare condition in

pregnancy, although it has been reported in patients with long standing type 1DM patients [3].

**Analysis of recent research and publications.** Lymphocytic hypophysitis or autoimmune hypophysitis is a disease characterized by lymphocytic infiltration of the pituitary gland, which eventually leads to destruction of pituitary tissue accompanied by various clinical presentations of pituitary dysfunction. This condition is frequently reported in women and has been associated with pregnancy with an increasing number of reported cases in recent years [4]. It is now clear that lymphocytic autoimmune hypophysitis can occur in females, adult males and children as well [5,6]. The natural history of lymphocytic hypophysitis is that of progression from inflammation, resembling pituitary mass to atrophy, seen as empty Sella on MRI [4, 5].

**Formulating the purpose of the article.** The purpose is to present a case of hypopituitarism and empty Sella in a Type 1 diabetic patient, diagnosed postpartum after long-suffering, who has achieved full term pregnancy and normal delivery is reported. Diagnosis of lymphocytic hypophysitis or antepartum pituitary necrosis was raised as the cause of the hypopituitarism.

**Presenting main material.** Case report: A 27 years old female patient known to have type 1DM for the past 7 years, on insulin treatment since diagnosis and on basal bolus insulin regimen for the last year. She presented to the Endocrine Clinic on December 6, 2012 for reevaluation. She had an uncomplicated spontaneous vaginal delivery 18 months ago. She gave birth to a healthy baby girl weighing 2850gm under epidural anesthesia. She has been suffering from amenorrhea since delivery to the date of consultation. She complained of cold intolerance, decreased appetite, easy fatigability, tiredness, laziness, persistent abdominal pain, nausea and vomiting. In addition, there were frequent attacks of hypoglycemia, and dizziness with changing position and difficulty to gain weight. Patient reported loss of weight 15kg (from 69 to 53kg) since delivery to the consultation date. She did not breastfeed her baby due to lack of milk production. Clinically, she appears tired, her blood pressure and pulse were 100/70 mmHg, 70

b/mand 90/60 mmHg, 80b/m sitting andstanding, respectively.Pulse was regular, and she was not febrile.Heart and Chest examination were unremarkable.Abdomen was soft with no organomegaly and nonspecific tenderness. Scanty hair growthis noted in axillaries and pubic areas.Lower limbs had no edema. Impression: type 1DM, secondary amenorrhea after normal delivery with persistent nausea, vomiting and abdominal pain.Laboratory investigationsare shown in Table I.

The patient had secondary amenorrhea after delivery, with low FSH, LH and prolactin.Such findings are not characteristics of early menopause or premature ovarian failure (POF). Pituitary MRI revealed empty Sella [Figure 1].

The patient was referred to the gynecology department for oral contraceptive pill (OCP) or assisted conception. Reassessment of the patient 3 months later revealed that she is still having the same clinical picture without any improvement. Laboratory investigations showed low normal levels of ACTH and cortisol (am)3.35 and 282, respectively. The patient was the nadmitted for further pituitary reevaluation and to rule out hypopituitarism. ACTH stimulation test was performed with 250mg Cosyntropin IV and the results are shownin Table II, thyroid function test was not performed at that time.

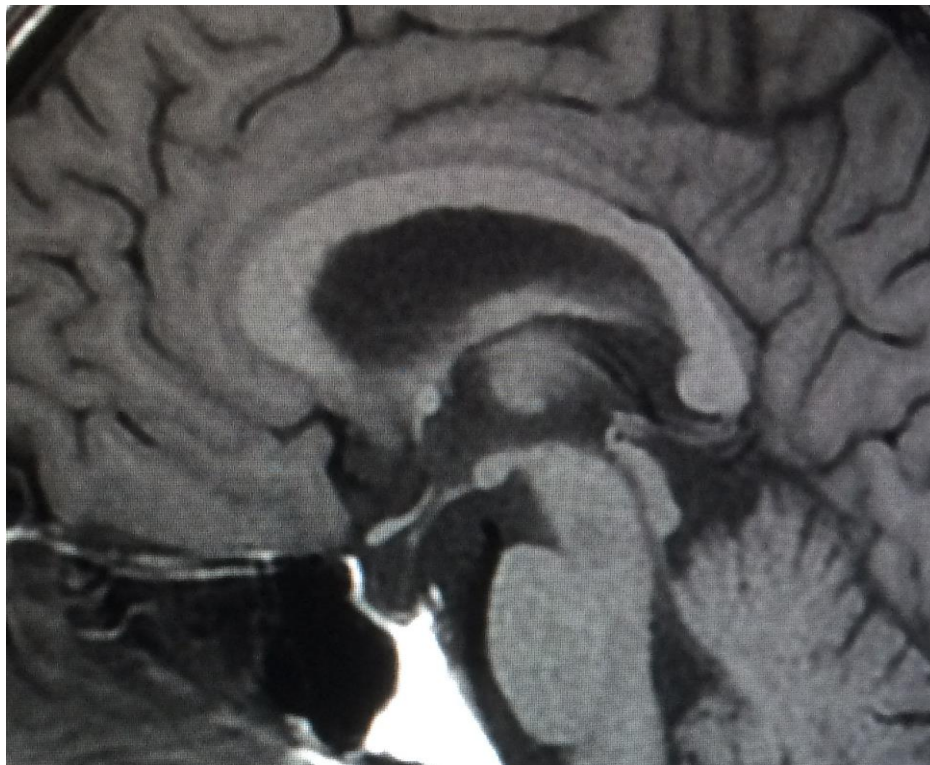

Figure 1 Pituitary MRI showing empty Sella.



The patient showed suboptimal response. Diagnosis of Partial Hypopituitarism with empty Sella was established.

Reviewing the medical history, she was well on regular follow-up in an Endocrine Clinic until she became pregnant. During pregnancy, she was admitted four times to the hospital. First admission was on November 6, 2010 at gestational age of 6 weeks with epigastric pain, nausea, vomiting without fever. Laboratory investigations are shown in Table I. Vital signs were within normal ranges. Patient was treated for UTI in pregnancy.

The patient continued to have persistent vomiting, nausea and abdominal pain that was explained as Hyperemesis Gravidarum. She was admitted for the second time to the medical ward at a gestational age of 16 weeks. She complained of sudden onset of severe headache of increasing intensity for the past 3 days. The headache was associated with severe vomiting and fever with no neck pain or blurred vision. Clinically, vital signs were stable, blood pressure was 110/70, and pulse was regular, 80 b/m. Heart, chest and abdominal examination were unremarkable. No neck rigidity or neurological deficit were observed. Fundi were normal. CSF was normal. Brain MRI (limited study without contrast because the patient was pregnant) was reported as normal, but pituitary gland showed slight bulging of its surface probably secondary due to hormonal changes. No evidence of intracranial mass, bleeding or acute infarction [Figure 2].

The severe headache, nausea, and vomiting continued and she developed fever during hospitalization [Figure 3].

Patient's blood sugar was controlled at low values with some tendency for hypoglycemia. Endocrine opinion was unexplained headache with normal CSF and Brain MRI. Laboratory results were within normal ranges, except for increased WBC count, neutrophils 63%, lymphocytes 30%. She was treated and discharged as a case of viral or nonspecific meningitis. Patient was instructed to take NSAIDs for headache, if needed. The patient continued to have similar complaints with recurrent frequent visits to the emergency room with new hypoglycemic attacks. She developed convulsions once and was admitted to the medical ward with

variation of blood sugar values, nausea, vomiting and abdominal pain. Clinically, she was stable. Laboratory investigations showed normal arterial blood gases and liver enzymes were: AST 89, ALT 105 (mostly drug induced), urine ketones were +3 and urine sugar was +3. She was treated as a case of uncontrolled blood sugar, given antiemetics and referred to the GI clinic for the persistent vomiting, nausea and abdominal pain.

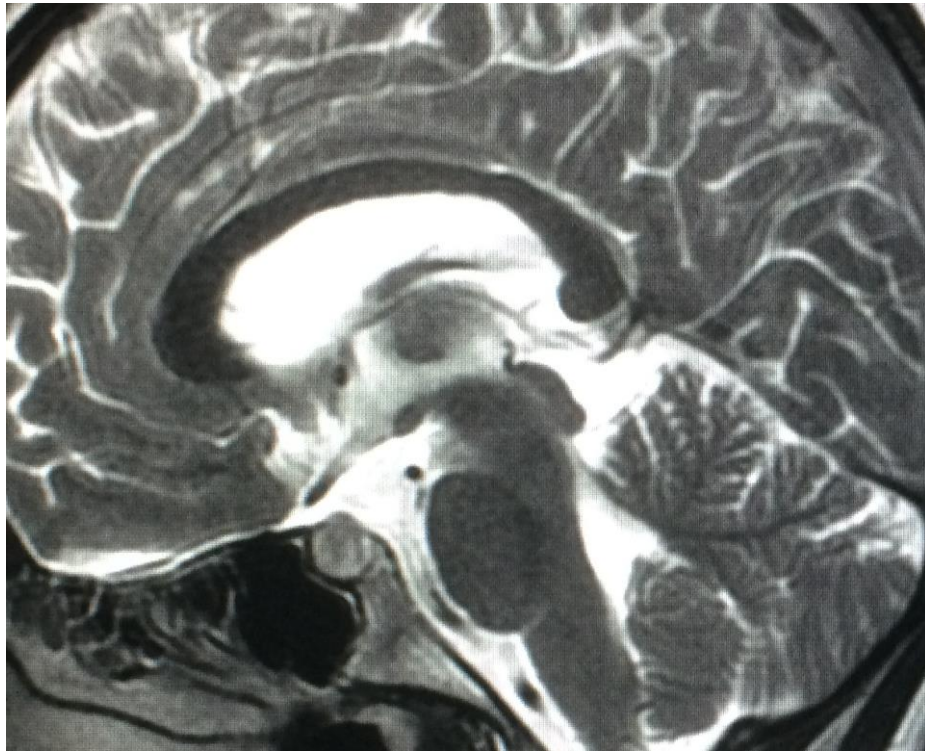


Figure 2 Brain MRI showing pituitary enlargement.

The clinical condition continued to be the same, without improvement. Patient was admitted to the hospital twice, once, she was admitted to the intensive care unit for severe vomiting, and supportive management was provided. Between admissions, she had recurrent and frequent visits to the ER with the same clinical picture until she gave birth. After delivery, her clinical picture did not improve much, nausea, vomiting, abdominal pain, tiredness, easy fatigability, weakness, decreased appetite, hypo and hyperglycemic attacks and shortness of breath on exertion were observed. Laboratory investigations of ACTH, Cortisol (am), thyroid stimulating hormone and prolactin values were: 2.76, 181, 0.5, 126, respectively [Table I].

Temperature, Pulse, Respiration and Blood Pressure Record

Patient Name: Taiseer mohid

File No: 5003013

Admission Date: 19.1.11

Room: 361

Weight: \_\_\_\_\_

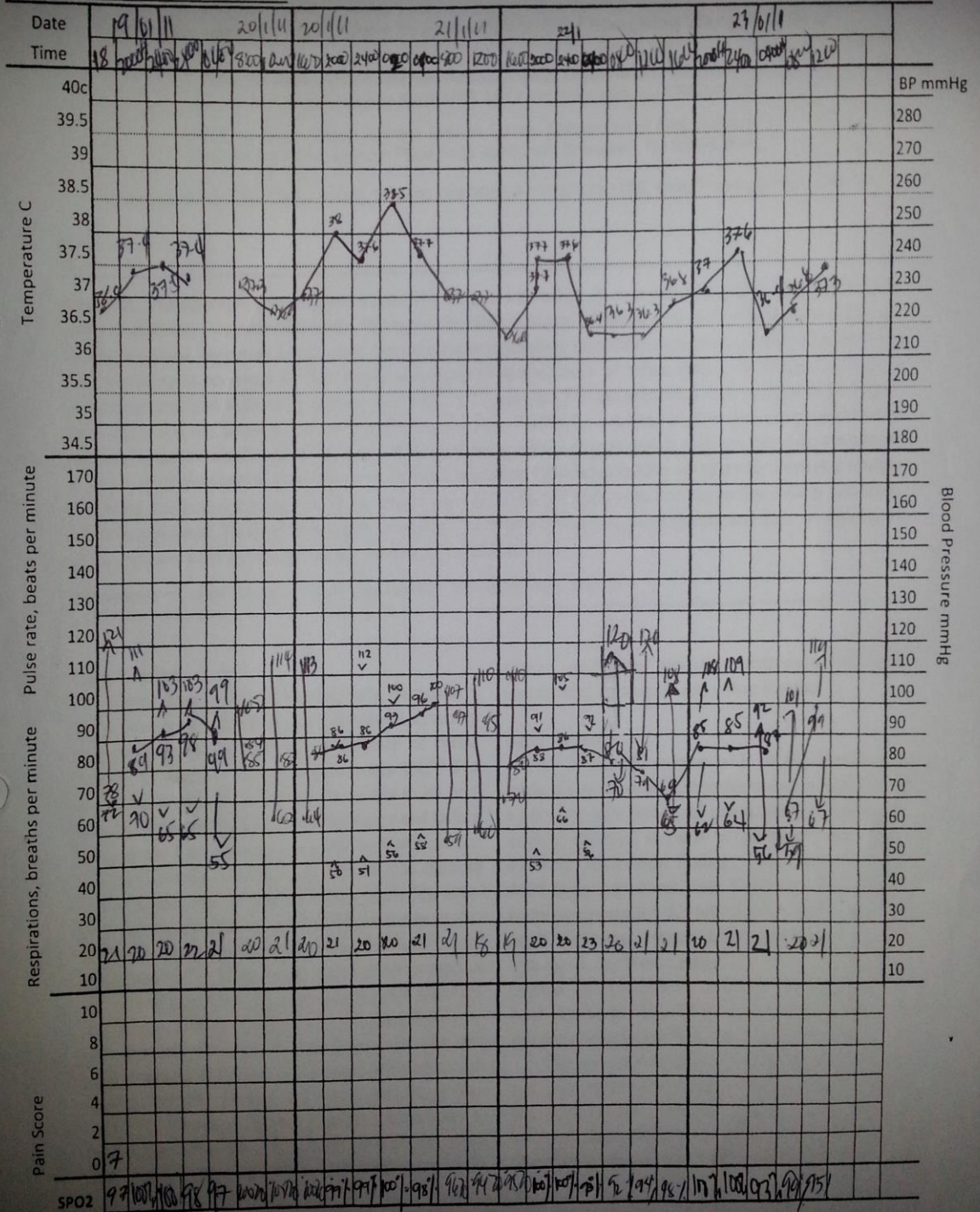


Figure 3 Temperature curve during first admission.

Table 1.

**Laboratory investigations throughout clinic visits and admissions**

Laboratory test	6-11-2010	19-1-2011	7-2-2011	20-7-2011	6-12-2012	19-2-2013	-3-14 2014
HBA1c(4.2-5.7%)	9.0				12.9	12.5	7
Cholesterol(mmol/L)	NA				6.37		
LDL-c (mmol/L)	NA				4,75		
AST (IU)	NA		89		94		
ALT (IU)	NA		105		129		
K+ (3.5-5.2) mmol/L	NA				4.77	4.3	3
Na+(136-145)mmol/L	NA		NA		138	132	143
Cl- (90-107) mmol/L	NA		NA		97	93	
ACTH (1.6-13.9)	-----		-----	2.76	6.8		
Cortisol(am)(171-536)	-----		-----	181	268		
TSH(0.27-4.2)mIU/L	-----		-----	0.5	1.8	-----	1.3
FT4	-----		-----	-----	----		5
FT3	-----		-----	-----	-----	-----	2.2
Prolactin(72-511)mIU/L	-----			126	28		
B Estradiol(46-607) mIU/L	----				17		
FSH (3.5-12.6)mu/ml	----				4.55		3.5
LH (2.5-12.5) mu/ml	-----				3.7	Normal	1.5
CBC	NA	WBC 14x10 <sup>3</sup>			Normal		
KFT	NA				Normal		
TTG abs	negative				negative		
Anti insulin Antibodies	-----				negative		
Hbs Ag	-----				negative		
HCV antibodies	-----				negative		
Urine analysis	WBC 29-33		++++ ketones +++ sugar		-----		
ABGs	-----		normal		-----		
Mg	-----				-----		
TPO antibodies	negative				-----		
Tg Antibodies	negative				-----		

The patient clinical picture described did not improve and she continued to visit the emergency room, internal medicine and obstetric gynecologic clinics. She was advised to seek psychiatric consultation for her condition. However, she was reevaluated by cardiologist, neurologist, nephrologist and gastroenterologist several times. Diagnoses of inflammatory pelvic disease and nephropathy were suggested. Nonetheless, abdominal CT-Scan showed no abnormalities. ECG showed low voltage and normal sinus rhythm [Figure 4].

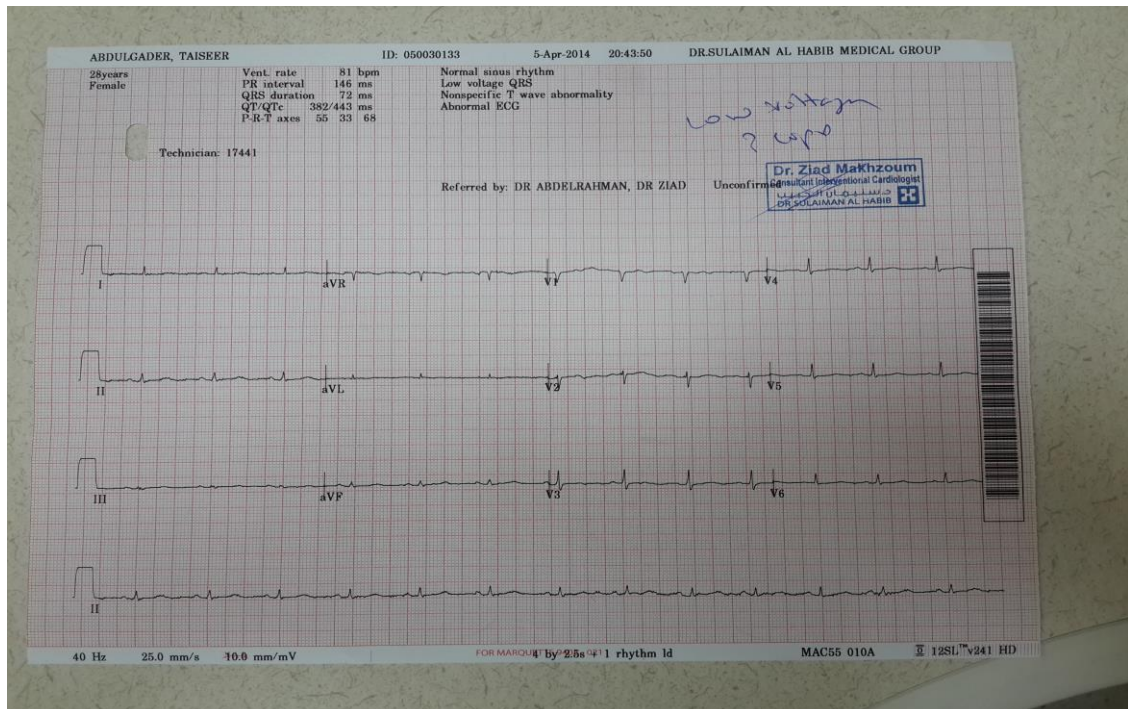


Figure 4. EKG showing low voltage amplitude

Echocardiography was normal. Brain MRI was performed because she developed left sided numbness and body ache. On examination, no neurologic deficits were detected and multiple sclerosis was suspected. MRI showed pituitary empty Sella [Figure 5a, 5b]. Epilepsy with gastric aura was then suggested, but the patient did not take the prescribed antiepileptic drugs.

Two years later, the diagnosis of Partial Hypopituitarism was established. She was prescribed hydrocortisone 10mg morning 5mg evening daily. Significant improvement of her condition was noticed and one month after the hydrocortisone replacement therapy, she was asymptomatic with good general condition.

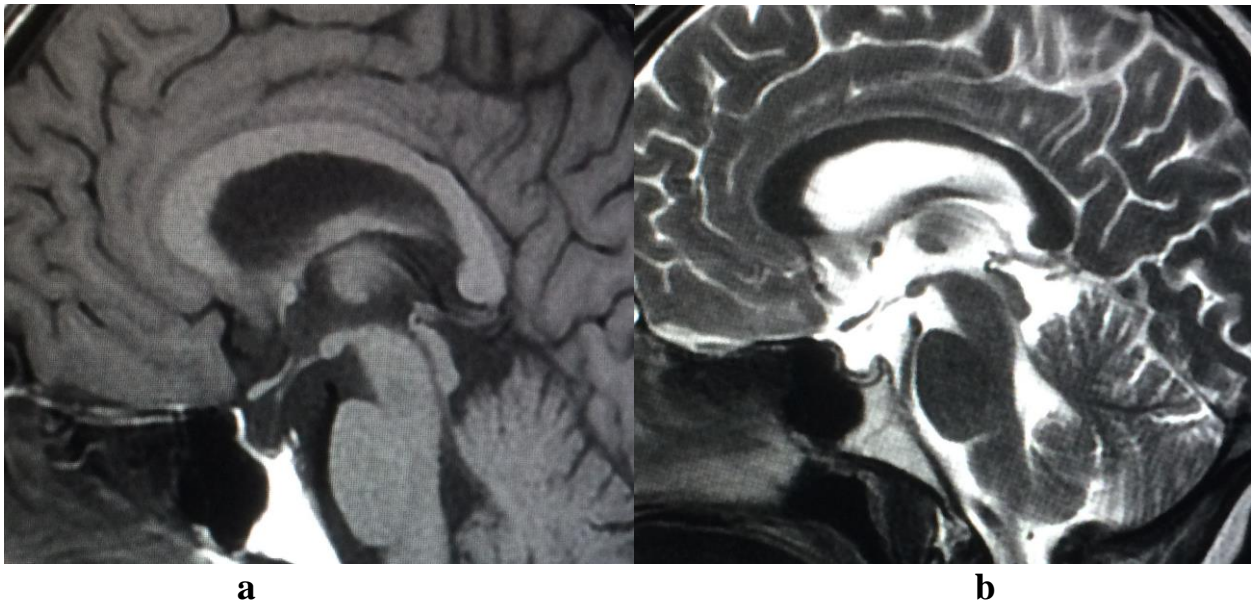

Figure 5 (a, b). Brain MRI showing empty Sella

A year later, she was free of symptoms with controlled blood sugar. Laboratory investigations were unremarkable except for the thyroid profile [Table 2], which supported the diagnosis of panhypopituitarism and she was prescribed thyroxine 100mcg daily, hydrocortisone 10mg daily and oral contraceptives (OCP).

Table 2 .

<b>ACTH stimulation test</b>		
Time	ACTH	Cortisol
Zero	1,86	153
30'		525
60'		660
90'		562
120'		560

Interpretation of the ACTH stimulation test:

If cortisol am > 470 - 500 Normal

Cortisol am <80-110 Adrenal insufficiency

Cortisol am 110-470, consider repeating the ACTH Stimulation test

If cortisol level >722, Normal response

If cortisol <510, suboptimal response

Two years later, the patient delivered a healthy baby. The pregnancy course was without complication and controlled blood sugar.

**Discussion:** Hypopituitarism is a state of endocrine partial or complete malfunction. It may be due to a disease of the pituitary, hypothalamus or even the surrounding structures [9]. It was first clinically described by Simmonds in 1914 [10]. Hypopituitarism may present as an acute onset disease with adrenal insufficiency or severe hypothyroidism. Therefore, admission and intensive care management is necessary, versus chronic diseases with signs and symptoms of pituitary mass lesion or progressive hormonal deficiency symptoms of target organ [11]. The described patient did not have a history of post-partum or antepartum hemorrhage but had a normal vaginal delivery with a healthy baby. Therefore, she cannot fall in the category of Sheehan's Syndrome; hence, she fits the category of hypopituitarism wherein pituitary autoimmunity or pituitary necrosis leads to hypopituitarism [1,10].

The pituitary autoimmune disorder; Lymphocytic Hypophysitis (LH) was first described by Goudie and Pinkerton in 1962. The first antepartum LH cases were reported in 1980 by Quencer and Mayfield [6]. Since that time, more than 700 cases were presented [6,11]. This condition usually affects women during pregnancy, postpartum period, non-pregnant women as well as men and children [6].

The natural history of Lymphocytic Hypophysitis is variable. Initially, the pituitary gland can enlarge and cause compressive symptoms as it undergoes inflammatory infiltration. Over time, the gland usually shrinks because of fibrosis and atrophy, ending with empty Sella. Most patients will have permanent Hypopituitarism. Nevertheless, there have also been reported cases of pituitary functions recovery [6, 12 and 13].

Is this a case of Lymphocytic Hypophysitis during pregnancy? - because she was on her second trimester of pregnancy! She developed severe headache, nausea, vomiting, general weakness with hypoglycemic attacks, and sensitive hyperglycemia (where only small doses of insulin are needed to control that) with

symmetrical pituitary enlargement which was seen in Brain MRI even contrast was not given. The patient's condition was explained as non-specific aseptic meningitis, most probably of viral origin, as was reported earlier [14, 15].

All throughout her pregnancy, since the first admission, she continued to have signs and symptoms of ACTH, Cortisol deficiency [18], which was overlooked until a year after delivery, when hydrocortisone replacement therapy was started.

In our patient, the headache was blamed on meningitis [14, 15]. While other symptoms such as fatigue, lethargy, nausea and vomiting were blamed on the pregnancy [16].

Death due to adrenal insufficiency have been reported in earlier series of cases as well as endocrine deficiency with 136 out of 152 patients showing, ACTH deficiency in 82, low TSH in 62, decreased Gonadotrophine in 59 and Prolactin deficiency in 50 patients [17]. Hyperprolactinemia can occur due to compression of pituitary stalk. Involvement of the posterior pituitary was also reported [10, 14, 15].

The endocrine deficiency in our patient was due to anterior pituitary hypopituitarism, initially manifested by amenorrhea, failure of lactation and later diagnosed as ACTH and TSH deficiency. Growth hormone and IGF1 were not evaluated at that time. Her symptoms during pregnancy and post-partum were mostly due to ACTH deficiency, which is the earliest and most frequent sign of pituitary deficiency [6]. Lymphocytic Hypophysitis that manifested in our patient occurred during the early second trimester, as there were no complications on the fetus or on the outcome of the pregnancy, which concluded at term with spontaneous vaginal delivery [11, 18].

This case is a diagnostic feature of autoimmune hypophysitis panhypopituitarism. Given the clinical picture of severe sudden onset of continuous headache for 3 to 4 days, nausea, vomiting, and signs of cortisol deficiency during pregnancy, with severe symptoms, which were out of the proportion to the size of



pituitary mass on imaging particularly, the presence of headache in the absence of acromegaly, apoplexy or malignancy [19].

The treatment of autoimmune hypophysitis is controversial [6, 11]. Steroid therapy has been advocated to treat the autoimmune mechanism which have not been histologically proven and efficacy is uncertain [18, 20].

When visual pathways are affected, a case can certainly be made for a short trial of steroid treatment where the combination of context of pregnancy pattern of hormone deficiency and imaging findings are all suggestive of hypophysitis [6, 18, 20].

Autoantibodies, or other autoimmune diseases are not present in the described patient like Celiac Disease, Thyroiditis, Autoimmune Hepatopathy, Systemic Lupus Erythematosus and anti-insulin antibodies, (anti-GAD and anti-islet antibodies were not tested) even if she has long standing Insulin Dependent DM and treated for that. The possibility of pituitary necrosis in a diabetic patient during pregnancy was raised in this patient. Pituitary necrosis during pregnancy is a very rare condition and unrelated to massive intra or postpartum hemorrhage, has only been reported in patients with long standing DM-1 and recently described in GDM [1, 3].

The clinical picture in the described patient is suggestive of pituitary necrosis; sudden onset of severe headache lasting 3-4 days in the early second trimester of pregnancy associated with severe nausea and vomiting. During hospitalization, she developed fever and low blood sugar with hypoglycemic attacks and increased sensitivity to insulin doses. Therefore, less insulin doses were given, but her blood sugar fell down to hypoglycemic levels when insulin dose was increased. Concurrently, hyperglycemia was observed when insulin was stopped or decreased.

Brain MRI showed symmetrical enlargement of pituitary gland but contrast. Despite continuous nausea, vomiting, abdominal pain with recurrent admissions and experiencing hypo- and hyperglycemic episodes during pregnancy, pituitary function was not evaluated. This was due to the already established diagnosis of

nonspecific or viral meningitis. Despite amenorrhea and lactation failure, symptoms were attributed to pregnancy and after delivery ascribed to gastrointestinal issues or psychiatric disorder as was reported earlier [21].

Pituitary gland, especially the anterior lobe, normally enlarges during pregnancy and the blood supply requirement increases [22]. When diabetic vasculopathy and hypercoagulability superimposes the aforementioned physiologic changes, the pituitary gland becomes more prone to ischemia and necrosis [1]. This is the most probable pathophysiological explanation of pituitary necrosis in diabetic pregnancy.

To date, reports of antepartum pituitary necrosis associated with DM are rare. Based on the described cases [3, 23], all pregnant cases associated with this condition have preexisting Insulin Dependent DM with a duration ranging from 1 to 25 years. Antepartum necrosis usually occurs in the third trimester of pregnancy. Common symptoms and signs that increase suspicion of pituitary necrosis are intractable headache and the Houssay phenomenon (frequent episodes of hypoglycemia caused by growth hormone and/or ACTH deficiency resulting in sudden decrease of insulin requirement) [3, 24 and 25].

The described case here is unique and distinguished from other previously described cases in that she developed the clinical picture of pituitary necrosis early in the 14 weeks of gestational age with subsequent picture of ACTH deficiency and hypoglycemic attacks with increased sensitivity to insulin.

The finding of empty Sella on MRI postpartum 9 months later, absence of antepartum or postpartum hemorrhage and completed pregnancy without complications. Additionally, a clinical picture of severe headache in early pregnancy with postpartum amenorrhea, and lactation failure suggest pituitary necrosis, hypopituitarism.

The clinical picture described here demonstrates either autoimmune lymphocytic-adenohypophysitis with panhypopituitarism and empty Sella. Either, antepartum pituitary necrosis as clinical picture developed in a patient known to have type 1 DM and related to pregnancy.

**Conclusions and perspectives of further research.** We conclude that any headache of sudden onset associated with nausea and vomiting during pregnancy and a suggested picture of pituitary insufficiency should be considered an alert of pituitary disorder that cannot be explained as pregnancy related symptoms, or non-specified meningitis. Furthermore, to be careful in interpreting images not specific to pituitary gland.

This conclusion was established based on the early steroids treatment that could prevent the progression of the pituitary destruction and/or early identification of the condition with early replacement therapy. This should prevent long-suffering of such patients.

### **References**

1. Park HJ, Kim J, Rhee Y, Park YW, Kwon JY. Antepartum pituitary necrosis occurring in pregnancy with uncontrolled gestational diabetes mellitus: a case report. *J Korean Med Sci.* 2010; 25:794-7
2. Hao J1, Liu M, Mo Z. *Case Rep Med.* 2012; 2012: 271345. doi:10.1155/2012/271345. Epub 2012 Sep 19. The Symptoms Get Worse after Pregnancy in Sheehan's Syndrome: A Case Report.
3. Tahrani AA1, West TE, Macleod AF. *ExpClinEndocrinol Diabetes.* 2007; 115:136-8. An unusual cause of severe hypoglycaemia in type 1 diabetes mellitus. Antepartum pituitary failure: a case report and literature review.
4. Rivera JA. Lymphocytic hypophysitis: disease spectrum and approach to diagnosis and therapy. *Pituitary.* 2006; 9:35-45.
5. Laway BA, Mir SA. Pregnancy and pituitary disorders: Challenges in diagnosis and management. *Indian J EndocrinolMetab.* 2013; 17:996-1004
6. Bellastella G, Maiorino MI, Bizzarro A, Giugliano D, Esposito K, Bellastella A, De Bellis A. Revisitation of autoimmune hypophysitis: knowledge and uncertainties on pathophysiological and clinical aspects. *Pituitary.* 2016; 19:625-642. Review.

7. Petersenn S, Quabbe HJ, Schöfl C, Stalla GK, von Werder K, Buchfelder M. The rational use of pituitary stimulation tests. *DtschArztebl Int.* 2010; 107:437-43.
8. Du X, Yuan Q, Yao Y, Li Z, Zhang H Hypopituitarism and successful pregnancy. *Int J ClinExp Med.* 2014. 15; 7(12): 4660-5.
9. Kim SY. Diagnosis and Treatment of Hypopituitarism. *EndocrinolMetab.* 2015; 30:443-55
10. Schneider HJ, Aimaretti G, Kreitschmann-Andermahr I, Stalla GK, Ghigo E. Hypopituitarism. *Lancet.* 2007; 369:1461-70
11. Caturegli P, Newschaffer C, Olivi A, Pomper MG, Burger PC, Rose NR Autoimmune hypophysitis. *Endocr Rev.* 2005; 26:599-614
12. Gao H, Gu YY, Qiu MC. Autoimmune hypophysitis may eventually become empty sella. *Neuro Endocrinol Lett.* 2013; 34:102-6.
13. Karaca Z, Tanriverdi F, Unluhizarci K, Kelestimur F, Donmez H. Empty sella may be the final outcome in lymphocytic hypophysitis. *Endocr Res.* 2009; 34:10-17.
14. Honegger J, Fahlbusch R, Bornemann A, Hensen J, Buchfelder M, Müller M, Nomikos P. Lymphocytic and granulomatous hypophysitis: experience with nine cases. *Neurosurgery.* 1997; 40:713-22
15. Matta MP1, Kany M, Delisle MB, Lagarrigue J, Caron PH. A relapsing remitting lymphocytic hypophysitis. *Pituitary.* 2002; 5:37-44
16. Biswas M, Thackare H, Jones MK, Bowen-Simpkins P. Lymphocytic hypophysitis and headache in pregnancy. *BJOG.* 2002; 109:1184-6
17. Quinkler M1, Beuschlein F2, Hahner S3, Meyer G4, Schöfl C5, Stalla GK6. Adrenal cortical insufficiency--a life threatening illness with multiple etiologies. *DtschArztebl Int.* 2013; 110(51-52): 882-888.
18. Karaca, Z., F. Tanriverdi, K. Unluhizarci, F. Kelestimur, Pregnancy and pituitary disorders. *Eur J Endocrinol.* 2010; 162: 453-475.
19. Howlett TA1, Levy MJ, Robertson IJ. How reliably can autoimmune hypophysitis be diagnosed without pituitary biopsy? *ClinEndocrinol,* 2010; 73:18-21

20. Karaca Z, Kelestimur F. The management of hypophysitis. *Minerva Endocrinol.* 2016; 41: 390-399.

21. Nwokolo, M and Fletcher J. A rare case of hypopituitarism with psychosis. *Endocrinol Diabetes Metab. Case Rep.* 2013; 2013:130007

20. Gao H, Gu YY, Qiu MC. Autoimmune hypophysitis may eventually become empty sella. *Neuro Endocrinol Lett.* 2013; 34:102-106.

21. Karaca Z, Tanriverdi F, Unluhizarci K, Kelestimur F, Donmez H. Empty Sella may be the final outcome in lymphocytic hypophysitis. *Endocr Res.* 2009; 34:10-17.

22. Dorfman SG, Dillaplain RP, Gambrell RD Jr. Antepartum pituitary infarction. *Obstet Gynecol.* 1979; 53:21S-24S

23. Balasuriya Chandima N.D.1, Fougner Stine L.1, Bjørgaas antepartum pituitary insufficiency in type 1 diabetes 1, 2013 // [www.endocrineabstracts.org/ea/0032/eposters/ea0032p224\\_eposterpdf](http://www.endocrineabstracts.org/ea/0032/eposters/ea0032p224_eposterpdf)

24. Hardy KJ, Burge MR, Boyle PJ, Scarpello JH. A treatable cause of recurrent severe hypoglycemia. *Diabetes Care.* 1994; 17:722-724

25. Alexander RI Fatal hypoglycaemia in a diabetic patient with pituitary necrosis. *Br Med J.* 1953;1 (4825):1416-418.

## References

1. Park, H.J. Kim, J. Rhee, Y. Park, Y.W. and Kwon, J.Y. (2010), “Antepartum pituitary necrosis occurring in pregnancy with uncontrolled gestational diabetes mellitus: a case report”, *J Korean Med Sci.*, vol. 25, p.794-797

2. Hao, J.1. Liu, M. and Mo, Z. (2012), 271345, doi:10.1155/2012/271345. “The Symptoms Get Worse after Pregnancy in Sheehan's Syndrome: A Case Report”, *Case Rep Med.*

3. Tahrani, A.A. West, T. E. and Macleod, A. F. (2007), “An unusual cause of severe hypoglycaemia in type 1 diabetes mellitus. Antepartum pituitary failure: a case report and literature review”, *Exp Clin Endocrin Diab*, vol. 115, pp.136-138.

4. Rivera, J. A. (2006), "Lymphocytic hypophysitis: disease spectrum and approach to diagnosis and therapy", *Pituitary*, vol. 9, pp.35-45.
5. Laway, B. A. and Mir, S. A. (2013), "Pregnancy and pituitary disorders: Challenges in diagnosis and management", *Indian J Endocrinol Metab.*, vol. 17, pp. 996-1004
6. Bellastella, G. Maiorino, M. I. Bizzarro, A. Giugliano, D. Esposito, K. Bellastella, A. and De Bellis, A. (2016), "Revisitation of autoimmune hypophysitis: knowledge and uncertainties on pathophysiological and clinical aspects", *Pituitary. Review*, vol. 19, pp. 625-642.
7. Petersenn, S. Quabbe, H. J. Schöfl, C. Stalla, G. K. von Werder, K. and Buchfelder, M. (2010), "The rational use of pituitary stimulation tests", *Dtsch Arztebl Int.*, vol. 107, pp. 437- 443.
8. Du, X. Yuan, Q. Yao, Y. Li, Z. and Zhang, H. (2014, 15), "Hypopituitarism and successful pregnancy", *Int J ClinExp Med.* , vol. 7(12), pp. 4660-4665.
9. Kim, S. Y. (2015), "Diagnosis and Treatment of Hypopituitarism", *Endocrinol Metab.* , vol. 30, pp. 443-455.
10. Schneider, H.J. Aimaretti, G. Kreitschmann-Andermahr, I. Stalla, G. K. and Ghigo, E. (2007), "Hypopituitarism", *Lancet*, vol. 369, pp.1461-1470.
11. Caturegli, P. Newschaffer, C. Olivi, A. Pomper, M. G. Burger, P.C. and Rose, N. R. (2005), "Autoimmune hypophysitis", *Endocr Rev.*,vol. 26, pp. 599-614.
12. Gao, H. Gu, Y. Y. and Qiu, M. C. (2013), "Autoimmune hypophysitis may eventually become empty sella", *Neuro Endocrinol Lett.*, vol. 34, pp. 102-106.
13. Karaca, Z. Tanriverdi, F. Unluhizarci, K. Kelestimur, F. and Donmez, H. (2009), "Empty sella may be the final outcome in lymphocytic hypophysitis", *Endocr Res.* , vol. 34, pp. 10-17.
14. Honegger, J. Fahlbusch, R. Bornemann, A. Hensen, J. Buchfelder, M. Müller, M. and Nomikos, P. (1997), "Lymphocytic and granulomatous hypophysitis: experience with nine cases", *Neurosurgery*, vol. 40, pp. 713-722.
15. Matta, M. P. Kany, M. Delisle, M. B. Lagarrigue, J. and Caron, P. H. (2002), "A relapsing remitting lymphocytic hypophysitis", *Pituitary*, vol. 5, pp.37-44.

16. Biswas, M. Thackare, H. Jones, M. K. and Bowen-Simpkins, P. (2002), "Lymphocytichypophysitis and headache in pregnancy", *BJOG*, vol. 109, pp. 1184-1186.
17. Quinkler, M. Beuschlein, F. Hahner, S. Meyer, G.Schöfl, C. and Stalla, G.K. (2013), "Adrenal cortical insufficiency - a life threatening illness with multiple etiologies", *Dtsch Arztebl Int.* , vol. 110(51-52), pp. 882-888.
18. Karaca, Z. F. Tanriverdi, K. and Unluhizarci, F. (2016), "Kelestimur, Pregnancy and pituitary disorders", *Eur J Endocrinol.* , vol. 162, pp. 453-475.
19. Howlett, T. A. Levy, M. J. and Robertson, I. J. (2010), "How reliably can autoimmune hypophysitis be diagnosed without pituitary biopsy?", *Clin Endocrinol.*, vol. 73, pp. 18-21.
20. Karaca, Z. and Kelestimur, F. (2016), "The management of hypophysitis", *Minerva Endocrinol.* , vol. 41, pp. 390 - 399.
21. Nwokolo, M. and Fletcher J. (2013), "A rare case of hypopituitarism with psychosis", *Endocrinol Diabetes Metab. Case Rep.*, vol. 2013, p.130007.
20. Gao, H. Gu, Y. Y. and Qiu, M. C. (2013), "Autoimmune hypophysitis may eventually become empty sella", *Neuro Endocrinol Lett.* , vol. 34, pp. 102-106.
21. Karaca, Z. Tanriverdi, F. Unluhizarci, K. Kelestimur, F. and Donmez, H. (2009), "Empty Sella may be the final outcome in lymphocytic hypophysitis", *Endocr Res.*, vol. 34, pp. 10-17.
22. Dorfman, S. G. Dillaplain, R. P. Gambrell, R. D. (1979), "Jr. Antepartum pituitary infarction", *Obstet Gynecol.* , vol. 53, pp. 21S-24S.
23. BalasuriyaChandima, N. D. and Fougner Stine, L. (2013), "Björgaas antepartum pituitary insufficiency in type 1 diabetes" [Online], available at: [www.endocrineabstracts.org/ea/0032/eposters/ea0032p224\\_eposterpdf](http://www.endocrineabstracts.org/ea/0032/eposters/ea0032p224_eposterpdf)
24. Hardy, K. J. Burge, M. R. Boyle, P. J. Scarpello, J. H. (1994), "A treatable cause of recurrent severe hypoglycemia", *Diabetes Care*, vol. 17, pp.722-724
25. Alexander, R. I. (1953), "Fatal hypoglycaemia in a diabetic patient with pituitary necrosis", *Br Med J.* , vol. 1 (4825), pp.1416-418.